

Case Report

Different Resorptive Patterns of Two Avulsed and Replanted Upper Central Incisors Based on Scanning Electron Microscopy and Stereomicroscopic Analysis: A Case Report

Marta Mazur ^{1,*}, Roberto Marasca ², Livia Ottolenghi ¹, Iole Vozza ¹, Francesco Covello ¹,
Andrea Zupancich ³, Emanuela Cristiani ³ and Alessia Nava ³

¹ Department of Oral and Maxillofacial Sciences, Sapienza University of Rome, Via Caserta 6, 00161 Rome, Italy; livia.ottolenghi@uniroma1.it (L.O.); iole.vozza@uniroma1.it (I.V.); francesco.covello@uniroma1.it (F.C.)

² Pediatric Dentistry Unit, Head and Neck Integrated Department, AOU Policlinico Umberto I of Rome, Viale Regina Elena 287/b, 00161 Rome, Italy; rmlsr@libero.it

³ Department of Oral and Maxillofacial Sciences, DANTE - Diet and ANcient TEchnology Laboratory, Sapienza University of Rome, Via Caserta 6, 00161 Rome, Italy; andrea.zupancich@uniroma1.it (A.Z.); emanuela.cristiani@uniroma1.it (E.C.); alessia.nava@uniroma1.it (A.N.)

* Correspondence: marta.mazur@uniroma1.it; Tel.: +39-346-841-1546

Received: 1 April 2020; Accepted: 18 May 2020; Published: 21 May 2020



Abstract: Dental trauma resulting in permanent tooth avulsion commonly affects the young population. The prognosis of replantation after avulsion depends on the natural history of inflammatory and replacement resorption. Several risk factors for type and onset of external resorption have been defined. This case study describes different resorptive patterns observed in two upper central incisors belonging to a single individual, avulsed in the same moment, and replanted after thirty-six hours of dry storage. The roots were analyzed by scanning electron microscopy and stereomicroscope imaging, to obtain an in-depth analysis of the resorptive pattern. The aim of this report is to: (i) underline the high variability in the incidence of root resorption after replantation across and within types of teeth and resorption; and (ii) underline the possible concurrence of different factors affecting the onset and type of resorptive pattern. In conclusion, an unpredictable pattern of resorption may account for the poor prognosis when teeth are replanted outside the current recommendations.

Keywords: tooth avulsion; dry storage; tooth replantation; resorptive pattern; root resorption

1. Introduction

Dental avulsion is a common event in children and adolescents, with a reported prevalence of 17.5% and it is higher in boys compared to girls [1]. The consequences of dental avulsion are many and can be associated with individuals' quality of life, psychological and social problems, and direct and indirect costs of treatment [1].

The prognosis of replantation after avulsion depends on the natural history of inflammatory and replacement resorption. A recent review of the outcomes of traumatic dental injuries showed that external root resorption (inflammatory/replacement) in patients with correctly managed replantation is high and ranges between 59% and 80% [2]. However, it is well known that when the tooth is replanted within the guideline's required criteria (very short extra-oral time and storage in an appropriate medium), such resorptive pattern could have slower progression with a better prognosis over time [3–6].

Despite this, in a considerable number of cases, it has been observed that dental replantation occurs with a certain delay and the outcome of these cases remains poorly addressed. Several risk

factors affecting the onset and the progression of external root resorption have been described [5,6]. A systematic review of the incidence of external resorption after avulsion and replantation suggested that many factors influencing the incidence of root resorption exist and that each patient and setting may have different outcomes [7,8].

To highlight the variability of root resorption patterns and to underline the possibility of other risk factors concurring into the onset and type of resorptive pattern, we present this case report, where different external root resorptions (inflammatory/replacement) were identified and analyzed by stereomicroscopy and scanning electron microscopy (SEM).

2. Case Presentation

The patient was an 11-year-old girl, who arrived at the Pediatric Dentistry Unit at Sapienza University of Rome, Italy, in May 2019, for a routine control after a trauma occurred in March 2018.

The trauma had been managed, until May 2019, by another institution and the only information reported to us were those provided by the patient's grandmother. The avulsion trauma occurred after a domestic accident fourteen months earlier. The teeth were dry-stored for thirty-six hours and replanted after an extra-oral endo treatment. No other information was available to us about the therapies provided to the child. In this case, report World Dental Federation (FDI) tooth numbering system was used.

In May 2019, the clinical examination showed over-eruption of tooth 11, poor aesthetics, the persistence of an amount of composite resin on the vestibular surface of the upper six, and poor oral hygiene. The girl's caregiver reported about a previous splint on the upper six that was not removed carefully, and it resulted in the persistence of some detectable amount of composite resin. The color of the incisors was assessed as shade A3 on the spectrophotometric 3D Master Vita Scale (SpectroShade, MICRO, Serial NHDL1407, MHT, Arbizzano di Negrar, Verona, Italy). On percussion the sound was dull on 11 and high on 21. The mobility of the two incisors was evaluated: 11 presented tooth mobility with Miller's classification three and no mobility was present on 21. The cone beam computed tomography (CBCT, brought by the patient without any information on the equipment and without the medical report) showed a different appearance of the two upper incisors' roots and of the alveolar bone (Figure 1). Figure 1 shows parasagittal images from CBCT scans of the two central incisors after nine months of follow-up. The upper row shows tooth 11 and the lower row shows tooth 21. Tooth 11 presents a complete resorption of the buccal cortical bone with an overall reduction in the buccal and palatal bone thickness. Tooth 21 shows a preserved cortical bone with partial thickness reduction.

The girl was concerned about her smile appearance and, as soon as we realized the negative outcome of the replantation, the teeth were extracted. Immediately after the extraction, a Maryland bridge was bonded to the palatal surfaces of the lateral incisors. The bridge offered a fixed and conservative therapeutic solution for the edentulous space in the adolescent patient. The available bone width, especially in correspondence of tooth 11 where a loss of buccal bone occurred after the trauma, will be evaluated later when the patient will request implant therapy.

Informed consent was obtained by the patient and the case study was approved by the local institutional ethics committee (approval n.3493). This article was performed in accordance with the ethical standards laid down in the 1964 Declaration of Helsinki and its later amendments.

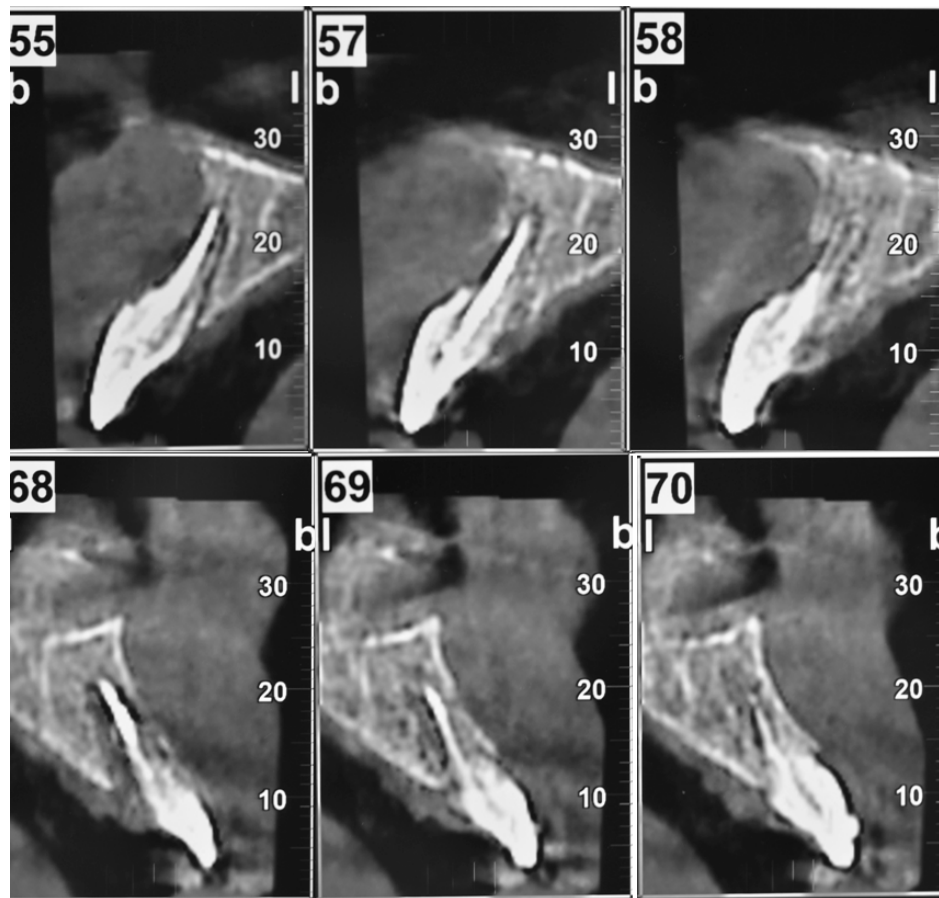


Figure 1. Series of parasagittal images from cone beam computed tomography (CBCT) of the two central incisors after 9 months of follow-up (13 December 2018); upper row tooth 11, lower row tooth 21.

Stereomicroscopy and SEM Images

After extraction, the organic material of the tooth was removed by exposure to an aqueous-based solution containing 2.5% NaOCl, for 24 h. The samples were dehydrated and prepared for stereomicroscopy (Zeiss Axio Zoom V16 binocular stereo microscope, oculars PI 10×/23, objective 1×/0.25 FWD 56 mm, Zeiss, Jena, Germany) and SEM evaluation, to illustrate the morphological characteristics of the two roots. Stereo microscopes allow us to generate three-dimensional images of the examined surface through optical microscopy in reflected light. In detail, we overlapped a series of ~100 photographs captured by moving on the vertical axis in multifocal mode. This examination allowed some areas of major interest to be further investigated through scanning electron microscopy (Hitachi TM3000-Tabletop Scanning Electron Microscope; magnifications 50 to 2000 at 15Kv acceleration voltage, Hitachi Ltd, Tokyo, Japan).

Figures 2 and 3 show stereomicroscopy images of the roots of teeth 11 and 21, respectively. The buccal side is more affected than the lingual one, with the gutta-percha filling exposed for more than 50% of its length in both roots (Figures 2B and 3B).

In the two cases, two different patterns of root resorption were observed, as follows:

- i. Tooth 21 experienced a heterogeneous root resorption, with the dentine lacunae extending more mesially and distally when compared to tooth 11 (Figure 3A,C);
- ii. The most apical portion of the root is almost preserved in tooth 11, while it is missing in tooth 21 as a consequence of the dentine resorption and the breakage of the gutta-percha filling;
- iii. The most cervical root portion on the lingual side of 21 is characterized by an isolated resorption cavity of 1.67×1.69 mm (Figures 3D and 4);

- iv. The resorptive pattern characterizing the root of the tooth 21 shows high heterogeneity (Figure 5). In this tooth, the external replacement resorption invaded the root by resorbing all the cementum and, irregularly, the dentine, that assumed a spurs appearance (Figure 5A,B). At higher magnifications (Figure 5C), these spurs are characterized by the presence of resorptive dentine lacunae and by the presence of treatment agents used by the dental practitioner before replantation. The dentine at the base of the spurs and at higher magnification (Figure 6) shows the same resorptive lacunae with dentine tubules surrounded by a hypermineralized collar of peritubular dentine;
- v. The microscopic structure of tooth 11 (Figure 7) is characterized by the same pattern of resorptive dentine lacunae as tooth 21 and by the same appearance of the dentine tubules (i.e., surrounded by a hypermineralized collar of peritubular dentine). Differently from tooth 21, here the cement preserves in some areas, preventing the resorptive reaction.

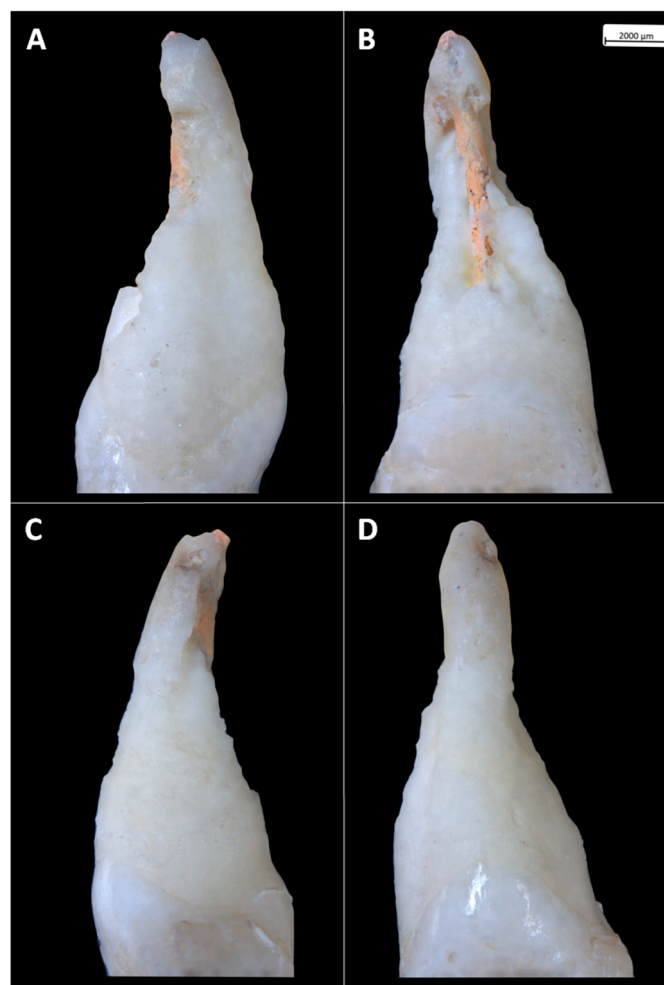


Figure 2. Stereomicroscopic images of tooth 11 root. (A) mesial view; (B) buccal view; (C) distal view; and (D) lingual view.

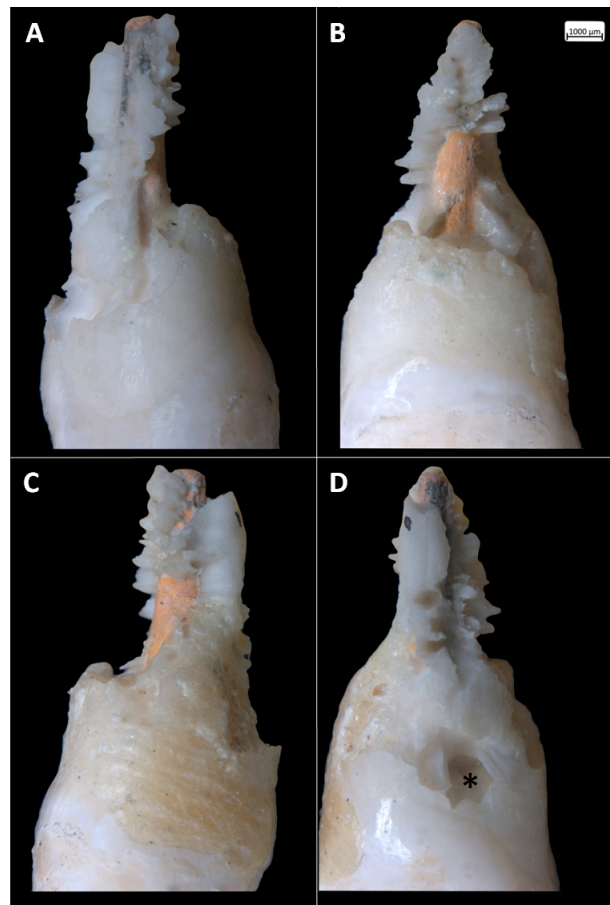


Figure 3. Stereomicroscopic images of tooth 21 root. (A) mesial view; (B) buccal view; (C) distal view; and (D) lingual view, * = isolated resorption cavity.




Figure 4. Scanning electron microscopy (SEM) images of tooth 21: (A) image at 60× magnification showing the dentine resorption cavity at the cervical palatal margin; (B) stereomicroscopy image of the same area; and (C) SEM magnification (800×) of the bottom of the cavity showing the resorptive reaction in the dentine. E = enamel, Ce = cementum, D = dentine.




Figure 5. SEM images of the apical third of the root of tooth 21, buccal view: (A) heterogeneous external replacement resorption characterizing the root, 50× magnification; (B) magnification of the dentine spurs (150× magnification); and (C) 500× magnification highlighting resorptive area of the dentine. * = treatment agents residuals, DL = dentine resorption lacunae.

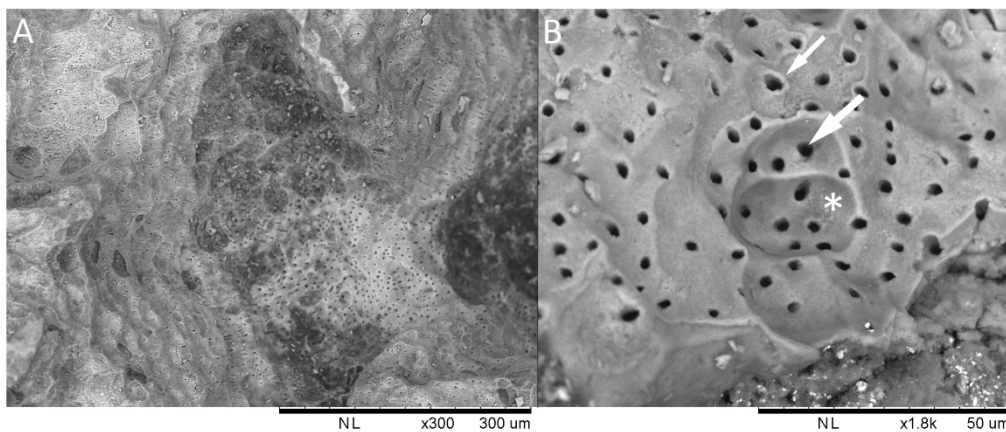


Figure 6. SEM images of the apical third of the root of tooth 21, buccal view: (A) image at 300× magnification showing the dentine resorption as a series of concaves surfaces; the dentine tubules are cut in different planes depending from the resorptive progression front; (B) magnification of the same area at 1800×. White star indicates a large resorptive lacuna; large white arrow point at a dentinal tubule hole; small white arrow indicates the hypermineralized peritubular dentine.

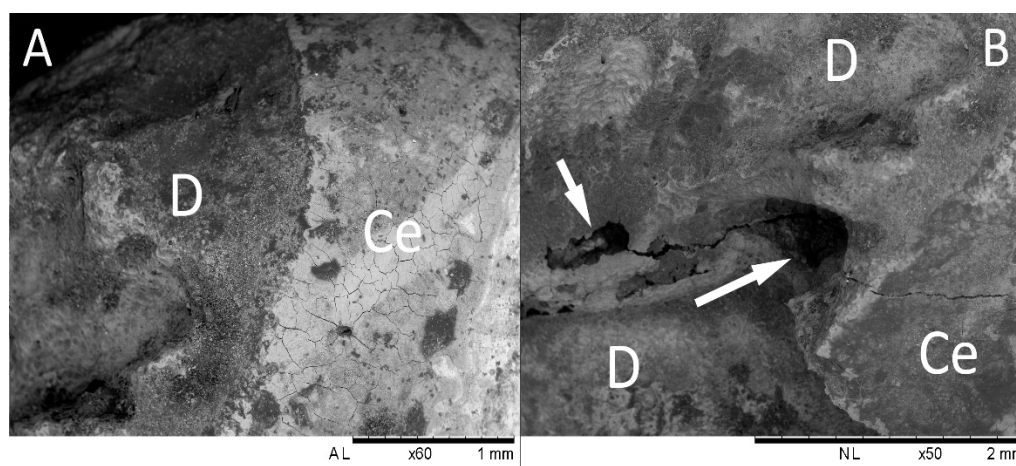


Figure 7. SEM images of tooth 11: (A) image at 60× magnification showing the boundary between the dentine under resorption (D) and the preserved root cement (Ce); (B) image at 50× magnification; other than the boundary described before, some craters penetrating the dentine are visible (arrows). The dentine-cement the boundary is visible.

3. Discussion and Conclusions

This case study reports different resorptive patterns developed in two central upper incisors from a single individual by means of SEM and stereomicroscopy imaging. The two teeth share the same history. The outcome of this case report indicates that an unpredictable pattern of resorption may account for the poor prognosis when teeth are replanted outside the current guidelines for the management of dental avulsion. It is worth noting that in the case of reimplantation of multiple teeth sharing the same history, the bad outcome of one tooth would not necessarily occur to the other ones.

A possible explanation for the observed differences in the two dental roots reactions can be searched in the factors affecting those teeth that are managed correctly. The major risk factors are the extra-oral time, the storage circumstances, the age of the patient, the open root apex, and the timing of pulp extirpation after replantation; all these have been widely documented in association with external root resorption onset and type [4–6,9]. This case report presented at the baseline all the already known risk factors, such as delayed replantation, incorrect storage, and the timing of pulp extirpation after replantation. Several studies investigated the effect of dry storage on periodontal ligament (PDL) cells' viability and subsequent onset of inflammatory resorption. Donaldson and Kinirons [5] have shown that periodontal ligament cells can be expected to survive a dry time of 15 min or less but are unlikely to survive a dry time of greater than 60 min [4,10]. Milk is a good storage media and it has been shown to preserve PDL cells for up to 8 h, however, Hank's balanced salt solution (HBSS), saliva, and saline are also indicated to keep periodontal tissue under good state until replantation [5,11]. The evidence shows that teeth with damage, contamination, and/or that are kept in dry storage longer than 15 min, increase the risk of early resorption [4]. The onset of the inflammatory resorption is more rapid than the replacement one, and the overall rate of root resorption in teeth with extended extraoral periods is significantly higher in younger patients [5,6]. Petrovic et al. examined the factors associated with avulsion injury in 51 children with 62 avulsed permanent incisors, in order to clarify the association between factors like history of the accident, concomitant injuries, age, gender, apical maturity of the root, replantation rate, storage media, extra-alveolar duration, endodontic treatment, compliance, and recall appointments response and the outcomes of the replantation. They showed that immature incisors exhibited significantly more complications compared with mature teeth with a lower survival rate [6]. The findings of Petrovic et al. were in accordance with the results of a previous study by Andersson et al., that showed that the progression of root resorption in teeth with prolonged extraoral time is strictly related to the age of the patient, with a higher rate in patients 17–39 years old at the time of the avulsive trauma, compared with 8–16 years old patients [12].

Moreover, a recent prospective clinical study on 165 patients documented that the risk of developing severe inflammatory resorption before the onset of endodontic therapy is directly affected by the pulpectomy time and is inversely proportional to age [13]. Similarly to the variability observed for external resorption in incorrectly managed cases, we show an unpredictable pattern of resorption also in those cases not fulfilling the recommended criteria. This may have an impact on the root surface prognosis. Our case confirmed the previous observation where the resorptive pattern has been related to factors like trauma, poor oral health, malocclusion, and parafunctional activity. Indeed, these are described as risk factors for developing a local hypoxic micro-environment that can affect the local vascular supply [13].

An observational clinical study on replanted ankylotic teeth reported an overall reduction of the buccal cortical bone thickness not corresponding to a reduction in the palatal bone, as observed in this study in tooth 21 [14]. On the other side, the complete resorption of the buccal cortical bone observed in tooth 11 and the development of a different resorptive pattern can be explained by the diverse weight of risk factors, like the cortical bone fracture and the local trauma during the avulsion. This was confirmed by the different percussion sound of the two incisors: dull on 11 and high on 21. To note, no data are reported on alveolar fractures as local risk factors for the prognosis of avulsed and replanted teeth.

In addition, we cannot exclude a possible role for systemic risk factors such as Th2 immunologic profile and macrophages type 1 and 2 (M1 and M2) ratio. In fact, several studies have evaluated the influence of a patient's Th2 immunologic profile on the occurrence of root resorption in avulsed and replanted teeth, both in cases managed with and without accordance to the guidelines. The results showed that after 1 year of follow up, the 82.98% of atopic patients did not exhibit root resorption, versus the 58.54% of the nonatopic ones [15–17]. Moreover, a recently published study showed the association between the macrophages type 1 and 2 (M1 and M2) ratio and root resorption. The M1s were associated with proinflammatory cytokines and the M2s to anti-inflammatory cytokines. Root resorption was enhanced by a higher M1/M2 ratio but was partially reduced by a lower M1/M2 ratio [18].

No data on Th2 immunologic profile and macrophages type 1 and 2 (M1 and M2) ratios are available for the herein presented case report. Despite the availability of official research, there is still some uncertainty on the clinical outcome of cases treated in accordance with the guidelines and of cases treated using alternative techniques and protocols. We believe that the preventive identification of local risk factors can be clinically relevant for the therapy over time and to obtain higher rates of good outcomes. However, the individual variability deserves further exploration to highlight other risk factors beyond those already known.

Author Contributions: Conceptualization, M.M., R.M.; methodology, L.O.; software, F.C., I.V.; validation, E.C., A.N.; formal analysis, A.Z., I.V.; resources, E.C.; data curation, M.M., A.N.; writing—original draft preparation, M.M.; writing—review and editing, R.M., L.O.; visualization, A.Z., F.C.; supervision, E.C.; project administration, A.N.; funding acquisition, E.C., A.N., A.Z. All authors have read and agreed to the published version of the manuscript.

Funding: This research was funded by the European Research Council, ERC Starting Grant Project HIDDEN FOODS, grant number 639286 awarded to Emanuela Cristiani).

Acknowledgments: Emanuela Cristiani, Alessia Nava and Andrea Zupancich acknowledge funding received for this project through the European Research Council (ERC Starting Grant Project HIDDEN FOODS, G.A. 639286 awarded to Emanuela Cristiani). SEM analysis performed at the Laboratory of Technological and Functional Analyses of Prehistoric Artefacts (LTFAPA), Department of Classics, Sapienza University of Rome.

Conflicts of Interest: The authors confirm that they have no conflict of interest.

Ethical approval: The case report was approved by the local institutional ethics committee (approval n.3493). This article was performed in accordance with the ethical standards laid down in the 1964 Declaration of Helsinki and its later amendments.

Informed consent: Informed consent was obtained from the individual participant included in this article.

References

1. Azami-Aghdash, S.; Azar, F.E.; Azar, F.P.; Rezapour, A.; Moradi-Joo, M.; Moosavi, A.; Oskouei, S.G. Prevalence, etiology, and types of dental trauma in children and adolescents: Systematic review and meta-analysis. *Med. J. Islam Repub Iran.* **2015**, *29*, 234. [[PubMed](#)]
2. Lam, R. Epidemiology and outcomes of traumatic dental injuries: A review of the literature. *Aust. Dent. J.* **2016**, *61*, 4–20. [[CrossRef](#)] [[PubMed](#)]
3. Andersson, L.; Andreasen, J.O.; Day, P.; Heithersay, G.; Trope, M.; DiAngelis, A.J.; Kenny, D.J.; Sigurdsson, A.; Bourguignon, C.; Flores, M.T. International Association of Dental Traumatology guidelines for the management of traumatic dental injuries: 2. Avulsion of permanent teeth. *Dent. Traumatol.* **2012**, *2*, 88–96. [[CrossRef](#)] [[PubMed](#)]
4. Panzarini, S.R.; Gulinelli, J.L.; Poi, W.R.; Sonoda, C.K.; Pedrini, D.; Brandini, D.A. Treatment of root surface in delayed tooth replantation: A review of literature. *Dent. Traumatol.* **2008**, *24*, 277–282. [[CrossRef](#)] [[PubMed](#)]
5. Donaldson, M.; Kinirons, M. Factors affecting the time of onset of resorption in avulsed and replanted incisor teeth in children. *Dent. Traumatol.* **2001**, *17*, 201–205. [[CrossRef](#)] [[PubMed](#)]
6. Petrovic, B.; Marković, D.; Peric, T.; Blagojevic, D. Factors related to treatment and outcomes of avulsed teeth. *Dent. Traumatol.* **2010**, *26*, 52–59. [[CrossRef](#)] [[PubMed](#)]
7. Souza, B.D.M.; Dutra, K.L.; Kuntze, M.M.; Bortoluzzi, E.A.; Flores-Mir, C.; Reyes-Carmona, J.; Felipe, W.T.; Porporatti, A.L.; De Luca Canto, G. Incidence of Root Resorption after the Replantation of Avulsed Teeth: A Meta-analysis. *J. Endod.* **2018**, *44*, 1216–1227. [[CrossRef](#)] [[PubMed](#)]
8. Brignardello-Petersen, R. There is probably high variability in the incidence of root resorption after replantation of avulsed teeth across and within types of teeth and resorption. *J. Am. Dent. Assoc.* **2019**, *150*, e15. [[CrossRef](#)] [[PubMed](#)]
9. Bastos, J.V.; de SouzaCôrtes, M.I.; Goulart, E.M.A.; Colosimo, E.A.; Gomez, R.S.; Dutra, W.O. Age and timing of pulp extirpation as major factors associated with inflammatory root resorption in replanted permanent teeth. *J. Endod.* **2014**, *40*, 366–371. [[CrossRef](#)] [[PubMed](#)]
10. Trope, M. Clinical management of the avulsed tooth: Present strategies and future directions. *Dent. Traumatol.* **2002**, *18*, 1–11. [[CrossRef](#)] [[PubMed](#)]
11. Blomlöf, L.; Lindskog, S.; Andersson, L.; Hedström, K.G.; Hammarström, L. Storage of experimentally avulsed teeth in milk prior to replantation. *J. Dent. Res.* **1983**, *62*, 912–916.
12. Andersson, L.; Bodin, I.; Sorensen, S. Progression of root resorption following replantation of human teeth after extended extraoral storage. *Dent. Traumatol.* **1989**, *5*, 38–47. [[CrossRef](#)] [[PubMed](#)]
13. Mavridou, A.M.; Hauben, E.; Wevers, M.; Schepers, E.; Bergmans, L.; Lambrechts, P. Understanding external cervical resorption patterns in endodontically treated teeth. *Int. Endod. J.* **2017**, *50*, 1116–1133. [[CrossRef](#)] [[PubMed](#)]
14. Tsukiboshi, M.; Tsukiboshi, T. Bone morphology after delayed tooth replantation—Case series. *Dent. Traumatol.* **2014**, *30*, 477–483. [[CrossRef](#)] [[PubMed](#)]
15. Roskamp, L.; Westphalen, V.D.; Carneiro, E.; Fariniuk, L.F.; Silva Neto, U.X.; Westphalen, F.H. Relationship between extra-alveolar time and atopy in the prognosis of the replantation of avulsed teeth. *J. Trauma* **2010**, *69*, 79–81. [[CrossRef](#)] [[PubMed](#)]
16. Roskamp, L.; Westphalen, V.P.; Carneiro, E.; Fariniuk, L.F.; Silva Neto, U.X. The positive influence of atopy on the prognosis of avulsed and replanted teeth despite differences in post-trauma management. *J. Endod.* **2011**, *37*, 463–465. [[CrossRef](#)] [[PubMed](#)]
17. Roskamp, L.; Silva Neto, U.X.; Carneiro, E.; Fariniuk, L.F.; Westphalen, V.P. Influence of Atopy in the Outcome of Avulsed and Replanted Teeth during 5 Years of Follow-up. *J. Trauma* **2017**, *43*, 25–28. [[CrossRef](#)] [[PubMed](#)]
18. He, D.; Kou, X.; Luo, Q.; Yang, R.; Liu, D.; Wang, X.; Song, Y.; Cao, H.; Zeng, M.; Gan, Y.; et al. Enhanced M1/M2 macrophage ratio promotes orthodontic root resorption. *J. Dent. Res.* **2015**, *94*, 129–139. [[CrossRef](#)] [[PubMed](#)]

