



Kent Academic Repository

Main, Alison, Kelly, Stephen W. and Manley, Graham (1999) *Articulation difficulties following maxillofacial surgery: A single case study*. In: *Pathologies of Speech and Language: Advances in Clinical Phonetics and Linguistics*. Wiley, pp. 299-306. ISBN 1-86156-122-9.

Downloaded from

<https://kar.kent.ac.uk/38944/> The University of Kent's Academic Repository KAR

The version of record is available from

This document version

UNSPECIFIED

DOI for this version

Licence for this version

UNSPECIFIED

Additional information

Versions of research works

Versions of Record

If this version is the version of record, it is the same as the published version available on the publisher's web site. Cite as the published version.

Author Accepted Manuscripts

If this document is identified as the Author Accepted Manuscript it is the version after peer review but before type setting, copy editing or publisher branding. Cite as Surname, Initial. (Year) 'Title of article'. To be published in *Title of Journal*, Volume and issue numbers [peer-reviewed accepted version]. Available at: DOI or URL (Accessed: date).

Enquiries

If you have questions about this document contact ResearchSupport@kent.ac.uk. Please include the URL of the record in KAR. If you believe that your, or a third party's rights have been compromised through this document please see our [Take Down policy](https://www.kent.ac.uk/guides/kar-the-kent-academic-repository#policies) (available from <https://www.kent.ac.uk/guides/kar-the-kent-academic-repository#policies>).

ARTICULATION DIFFICULTIES FOLLOWING MAXILLOFACIAL SURGERY: A SINGLE CASE STUDY

ALISON MAIN

Kent & Canterbury Hospitals NHS Trust and University of Kent at Canterbury

STEVE KELLY

University of Kent at Canterbury

GRAHAM MANLEY

Canterbury & Thanet Community Healthcare Trust

INTRODUCTION

Hypernasality and inaccurate tongue placement are common causes of poor speech intelligibility. The velum controls nasal coupling and hence resonance, and forms an essential seal, allowing the build up of intra-oral pressure required for obstruent sounds. Velopharyngeal insufficiency (VPI), the inability to make adequate velopharyngeal closure, may result from either structural or neurological abnormalities (Albery & Russell, 1990).

The tongue is the most versatile of the articulators, being involved in the production of all vowels and the majority of consonants. By altering tongue position and shape, the size of the oral cavity, and hence its resonating characteristic, changes, and different sounds are created. In order to speak, these complex movements must be coordinated with the controlled movement of the other articulators. Any errors in coordination, speed of movement, shape, or place of tongue contact will cause distortion and speech intelligibility will be affected.

Objective measurement of these parameters can be difficult. Two new systems have been developed by the University of Kent Medical Electronics Research Team, Kent & Canterbury Hospital Speech & Language Therapy Department and Canterbury & Thanet Community Dental Department. SNORS (Super Nasal Oral Ratiometry System) measures both nasal and oral airflow during speech, allowing the very rapid movement of the velum to be inferred. Linguagraph is a clinical electropalatography system, which measures tongue-palate contact.

A single case study is presented on a patient with whom both systems have been used.

CASE HISTORY

TW was a 52-year-old male, diagnosed as having carcinoma of the right tonsil, extending to the anterior border of the soft palate and the tongue base, in June 1995. He was treated with chemo- and radiotherapy, but a year later this recurred. Surgical excision included the right tonsillar fossa, tongue base, soft palate to the uvula, a right partial pharyngectomy and right partial mandibulectomy. He also had a right selective neck dissection preserving the

accessory nerve. The defect was reconstructed with a pectoralis major myocutaneous flap and he had a temporary tracheostomy.

Three months post surgery, TW was left with mild dysphagia, limited sensation on the right of his oral cavity, and a reduction in the intelligibility of his speech. He was very hypernasal: some palatal movement could be observed, but he did not seem able to sustain closure. Assessment using SNORS confirmed this.

SNORS

SNORS overcomes the limitations of nasal anemometry by using high-speed sensors to detect sudden changes in airflow caused by rapid movement of the velum. Also, the effect of speech intensity is overcome by measuring both the nasal and the oral airflow. This allows "nasalance", the amount of nasal airflow as a percentage of total airflow, to be calculated (McLean, Kelly & Manley, 1997). Therefore, using SNORS, coordination and duration of velopharyngeal closure can be inferred. Simultaneous sound recording allows this to be related to speech outcome.

Real-time visual feedback indicates nasal and oral components of airflow on a bar display, allowing the patient to visualise nasal escape. Maximum airflow and targets are provided. SNORS can also record and compare data taken at different times, to objectively measure change. A "test" assessment uses ten prompt words, chosen to show how effective velopharyngeal closure is (Ellis, et al, 1978), and the resulting data can be analysed and displayed in graphical form.

THE TRIAL

The trial compared the use of conventional speech and language therapy with SNORS biofeedback. TW was given a six-week block of each.

Conventional exercises included sucking and blowing, contrasting obstruents with nasals, and articulation exercises, to encourage opening of the mouth and more precise articulation. Therapy also focused on self-monitoring, to raise awareness of the sensation of palatal movement, and of auditory differences between oral and nasal resonance. TW found these easy to detect, as he is an ex-professional musician. All exercises were practised at home, with therapy once a week for motivation and encouragement.

SNORS biofeedback therapy, using the bar display, followed. Assessment had shown that TW could make velopharyngeal closure, but was unable to maintain this. The hypothesis was that enabling TW to visualise velopharyngeal closure would increase awareness of velar movement, and accompanying sensation. TW could be helped to increase duration of closure. Work started on sustained vowels. Initially, the level of nasal airflow was comparable to oral airflow. TW was encouraged to increase the oral, indicated by an extension of the oral bar, while maintaining and/or reducing the nasal airflow. Small adjustments that TW tried could be seen to either work or not. As this task became easier, TW's target level of nasal airflow was reduced.

TW was repeatedly asked to explain what was happening, and what that felt and sounded like. He was asked to reproduce the sensations and the sounds, first with, and as he became more practised, without the visual image. Therapy progressed

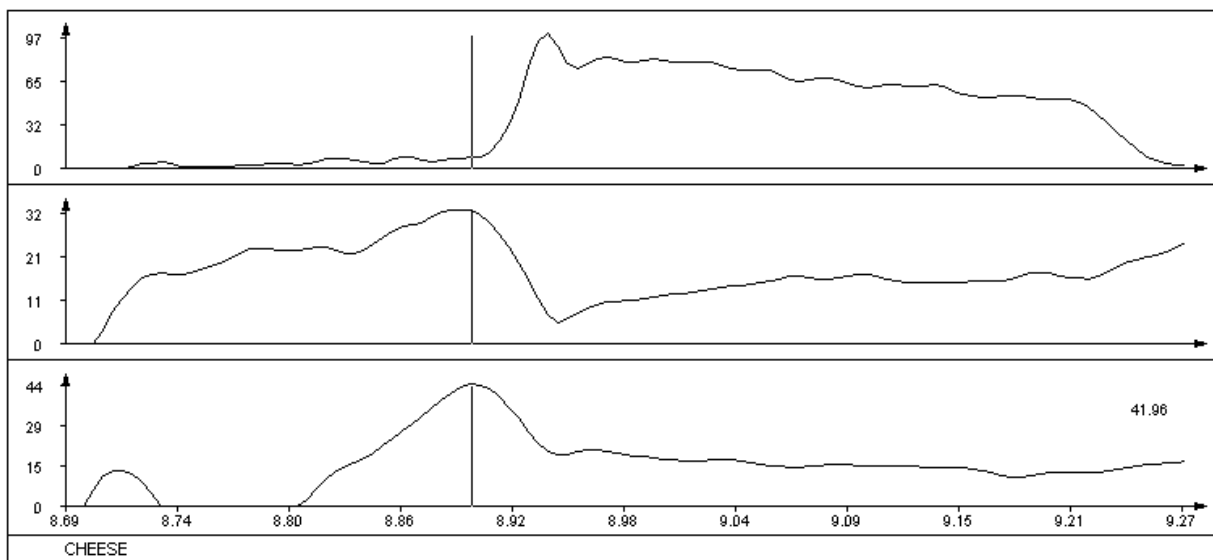
from sustained vowels to obstruent CV syllables. Initially TW was unable to make velopharyngeal closure, and thus build up sufficient intra-oral air pressure. Considerable progress was made in reducing nasal escape during the closed phase of the plosive, allowing an increase in oral air pressure, and a stronger oral release. Obstruents in other word positions, and in polysyllabic words, were then attempted. Changes and improvements were recorded throughout this therapy, and a final assessment was carried out.

TRIAL RESULTS

Assessment was carried out, using SNORS, prior to and following conventional and SNORS therapy, and nasalance was calculated. TW was required to say ten words. Because there is variability between repeated recordings made by individual subjects (Folkins, 1986), three recordings were made on each occasion, and the average used. Examples of baseline and final recordings of the assessment word “cheese” are shown in Figures 1 and 2.

The top trace shows the amplitude of the speech signal, detected by microphones. The middle trace shows nasal airflow, and the lower trace oral airflow. Note that the scale for each trace is different. The maximum value on the y-axis is 100%, but a smaller range is used in each case, to show maximum detail. Although peaks may look the same amplitude, they are generally different. The x-axis represents time, in seconds, and is the same for all traces. A measurement cursor has been placed at the point of maximum oral airflow, and the nasalance at this point is indicated.

Fig 1: Baseline recording of TW “cheese”. Top trace: speech envelope, middle trace: nasal airflow, bottom trace: oral airflow.



In Figure 1, the oral airflow initially shows a small peak, as TW makes alveolar closure for the affricate, /tʃ/. This is followed by the closure, shown as 0% oral airflow, and the release, shown as a peak. Oral airflow continues to the end of the word. This general pattern is what would be expected in the normal production of this word.

However, the nasal airflow shows an abnormal pattern, with nasal airflow continuing throughout the closure phase for the affricate. The fairly high levels may be due to attempts to increase intra-oral air pressure, and there is a peak of nasal airflow corresponding to the

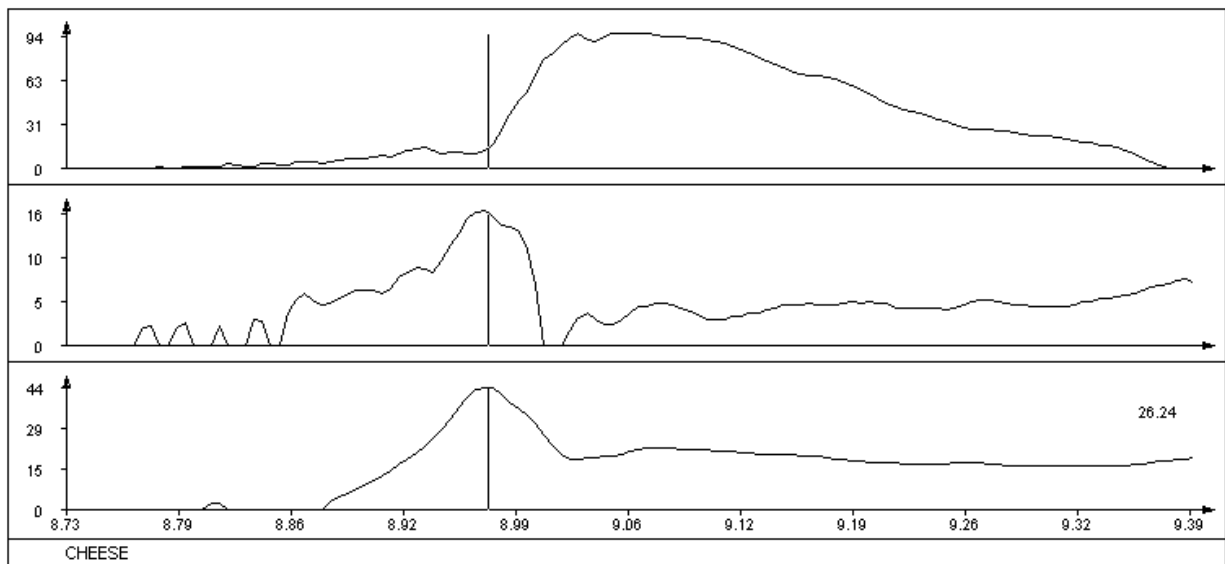
oral peak. There is an attempt at velopharyngeal closure following the affricate, where the trace dips, but closure is incomplete and fleeting. Nasal airflow rises during the vowel, /i/, and remains greater than oral during the final fricative, /z/. The rise in both airflows at the end of the word is caused by exhalation.

The consequential speech sound trace shows low level sound during the closure phase of the affricate, due to nasal emission. The sound level builds slightly during the affricate, and peaks with the onset of voicing, remaining high during the vowel, and decaying during the final fricative.

Following conventional therapy, nasal airflow was slightly reduced, suggesting a better approximation, though velopharyngeal closure was still not achieved.

A final assessment was made following SNORS biofeedback therapy. This shows substantial improvement.

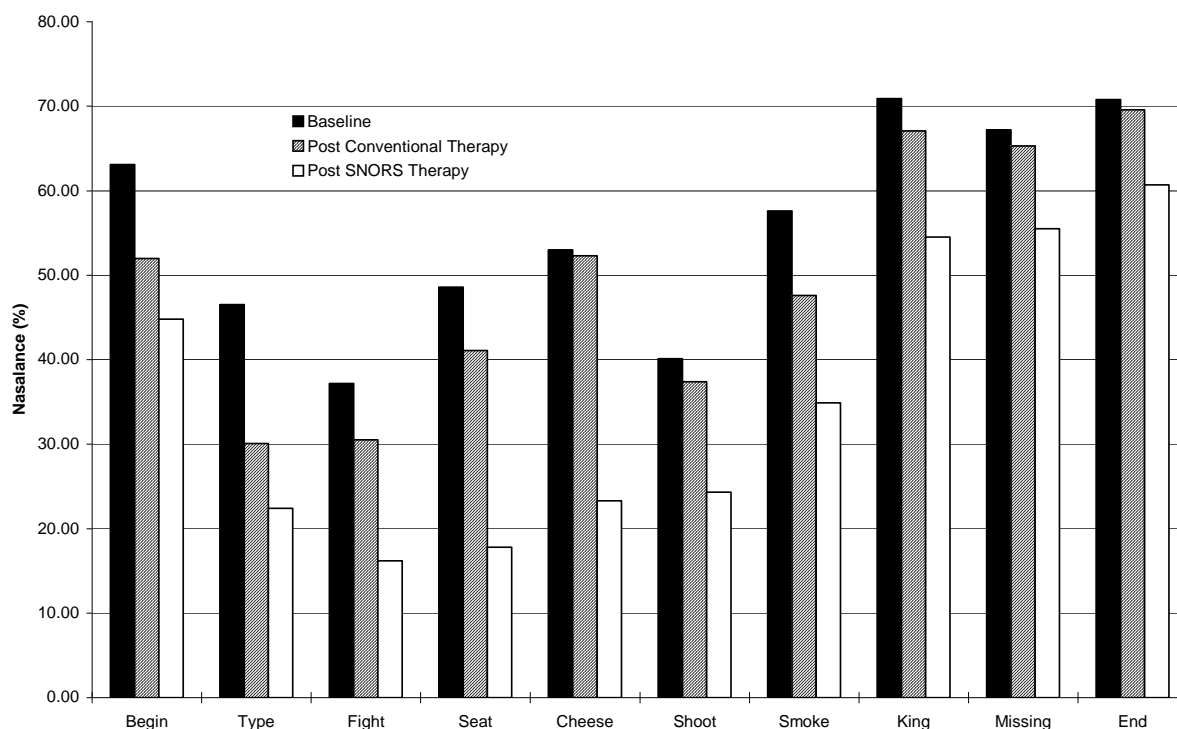
Fig 2: TW "cheese" following SNORS biofeedback therapy. Top trace: speech envelope, middle trace: nasal airflow, bottom trace: oral airflow.



In Figure 2, the overall oral airflow pattern is the same. Nasal airflow is reduced and is virtually zero during most of the oral closure. The periodic small peaks here may indicate vibration of the velum, much as would happen during snoring, suggesting that the velum has reduced tone. Closure is not maintained during the plosive, but does occur immediately after it. Although absolute closure is brief, nasal airflow remains very low throughout the remainder of the word, indicating a close approximation to closure.

Figure 3 shows the nasalance values for all ten words at the three assessment points.

Fig 3: Nasalance Summary for TW



It can be clearly seen that for the majority of words, there is some reduction in nasalance following conventional therapy, but a much greater reduction after SNORS therapy. The significance of this greater improvement was assessed, using the Chi Squared test, and found to be highly significant ($p < 0.001$).

However, TW's speech remained somewhat hypernasal, with reduced intelligibility. TW had a very high hard palate, and large oral cavity, so it was probably difficult to build up oral pressure. It was decided to try a built-up palate to decrease oral cavity size. This did not reduce hypernasality, but articulation nevertheless improved. Surgery may have affected tongue-palate contact, but the resulting articulation difficulties had been masked by TW's dominant hypernasality. Hence, TW was fitted with an electropalatography palate.

LINGUAGRAPH

Electropalatography is an instrumental technique for determining tongue/palate contact (Hardcastle, et al 1989, MorganBarry, 1989). The system used was the Kent Linguagraph (Kelly & Main, 1997, Main, Kelly & Manley, 1997). This clinical system works with a PC and standard interface card. Features include: a large, bright display (which can be single, two channel or full screen), and the facility to record and replay data. The system is easy to use for both therapy and assessment. Electropalatography gives the therapist an objective view of tongue/palate contact, and enables accurate diagnosis of the degree and manner of difficulty.

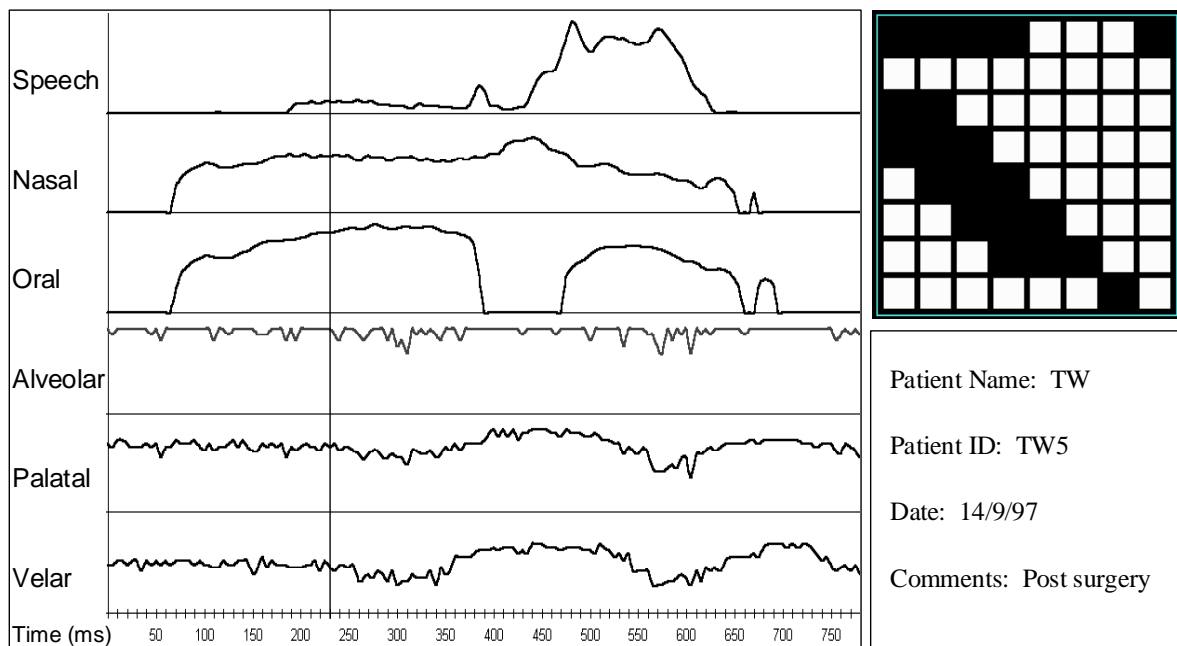
Linguagraph assessment

TW was making almost continual tongue/palate contact on the right, while using the left side of his tongue to compensate. Weakness and lack of sensation on the right of his oral cavity was the probable reason for this peculiar articulatory pattern. The effect on TW's articulation was slurring and imprecision of consonants. An illustration of TW's production of /s/ appears in Figure 4 below. The necessary groove is achieved on the left, and in a retracted position.

MULTIPARAMETER ASSESSMENT

Simultaneous assessment using SNORS and Linguagraph would have enabled more accurate diagnosis of TW's speech difficulties, and better targeting of therapy. Initially this was not possible. However, during the course of TW's therapy period, further developments by the team enabled simultaneous recording and analysis. A SNORS/Linguagraph recording was made.

Figure 4: SNORS/Linguagraph recording of TW "smoke". Speech, airflow and tongue-palate contact trends on the left, as labelled; electropalatography snapshot and patient details to the right.



In Figure 4, showing the word "smoke", the top trace is the envelope of the speech sound and the next two represent the nasal and oral airflows. The bottom three traces show the total lingua-palatal contact in each of the alveolar, palatal and velar regions (Jones and Hardcastle, 1995). To the right is a snapshot of the tongue contact pattern at the point indicated by the cursor.

Looking at the speech waveform, we see low-level sound at the start, representing the voiceless fricative /s/, followed by a small peak, as TW makes bilabial closure for the /m/. The sound level rises, during the /m/, and is sustained during the diphthong /e→Y/. Sound level drops, during the closure for the /k/, which is released silently.

Although oral airflow stops during the nasal /m/, the nasal airflow persists throughout the word, except for a brief closure just prior to the final plosive /k/. Tongue contact, in the alveolar region, is virtually 100% at all times. In the palatal and velar regions, it is also high, falling slightly for the fricative /s/ and the /Y/ part of the diphthong. Detail, such as the grooving for the /s/, can only be seen in a complete contact pattern snapshot. This is provided at the cursor position (maximum contact for /s/).

These results reflect TW's impaired velar and lingual function.

SUMMARY AND CONCLUSION

Radical maxillofacial surgery can have a detrimental effect on speech production. The function of various articulators may be impaired and sensation reduced. In this case, both tongue and velum were affected. The use of SNORS proved invaluable, both as an assessment and therapy tool.

Objective analysis, using SNORS, provided clear graphical and numerical evidence of improvement in velopharyngeal function following conventional therapy, where it was barely detectable subjectively. SNORS biofeedback, raised TW's awareness of remaining function, and enabled him to maximise this to improve velopharyngeal closure. The ability to monitor even small changes was motivating for TW and his therapist. The significant reduction in nasal airflow, following this biofeedback therapy, was accurately determined using SNORS.

The initially severe and dominant hypernasality masked TW's other articulatory difficulties. As these became more apparent, further assessment was carried out using Linguagraph, to determine their precise nature. This confirmed that TW had a unilateral weakness and demonstrated his peculiar articulatory patterns. It would not have been possible to predict such patterns from the resulting speech outcome. A course of Linguagraph therapy was planned. However, TW returned to full-time employment and has subsequently left his manual job to take up a managerial post. Since the completion of this therapy, TW has maintained the improvements made.

Despite his remaining articulation difficulties, TW is very pleased with his level of intelligibility, and reports that his speech rarely causes difficulties. So the outcome for him has been very good. However, if it had been possible to combine electropalatography with SNORS in initial assessment of TW's speech, targeting of therapy might have been different, and the improvements to intelligibility might have come sooner.

ACKNOWLEDGEMENTS

Thanks are due to Dr Hamid Mirlohi, Dr Calum McLean, M. Jean Skoda, and Mr Tim Lewis, at the University of Kent, for their work in the development of SNORS and Linguagraph. Also Mr Chris Hendy, Consultant Maxillofacial Surgeon, for his helpful comments and Dr Rosemarie Morgan Barry, Consultant Speech & Language Therapist, for encouragement and advice.

CORRESPONDENCE ADDRESS

Mr S. W. Kelly or Ms A. Main
Electronic Engineering Laboratory
University of Kent
Canterbury
Kent
CT2 7NT
Telephone: 01227 764000
Fax: 01227 456084

REFERENCES

- Albery E & Russell J (1990). Cleft palate and orofacial abnormalities. In Grunwell P (Ed), *Developmental Speech Disorders*. London: Whurr, Chapter 4, 63-82.
- Ellis RE Flack FC Curle HJ & Selly WG (1978). A system for the assessment of nasal airflow during speech. *British Journal of Disorders of Communication*, 13:1, 31-40.
- Folkins JW (1986). Issues in speech motor control and their relation to the speech of individuals with cleft palate. *Cleft Palate Journal*, 22, 106-122.
- Hardcastle W J Jones W Knight C Trudgeon A & Calder G. (1989). New developments in electropalatography: a state of the art report. *Clinical Linguistics and Phonetics*, 3, 1-38.
- Jones W & Hardcastle WJ (1995). New developments in EPG3 software. *European Journal of Disorders of Communication*, 30, 183-192.
- Kelly SW & Main A (1997). SNORS and Linguagraph. *Royal College of Speech and Language Therapists Bulletin*, May 1997, Pg. 7.
- Main A, Kelly S & Manley G (1997). Teaching the tongue and looking at listening. *Royal College of Speech and Language Therapists Bulletin*, Nov 1997, 8-9.
- McLean CC Kelly SW & Manley MCG (1997). An instrument for the non-invasive objective assessment of velar function during speech. *Medical Engineering & Physics*, 19:1, 7-14.
- MorganBarry RA (1989). EPG from square one: An overview of electropalatography as an aid to therapy. *Clinical Linguistics and Phonetics*, 3, 81-91.