

# Kent Academic Repository

## Full text document (pdf)

### Citation for published version

Kortteenniemi, Aaron and Lehto, Soili M. and Javadi, Amir-Homayoun (2018) Delayed, distant skin lesions after transcranial direct current stimulation. *Brain Stimulation* . ISSN 1935-861X.

### DOI

<https://doi.org/10.1016/j.brs.2018.10.018>

### Link to record in KAR

<https://kar.kent.ac.uk/70243/>

### Document Version

Author's Accepted Manuscript

#### Copyright & reuse

Content in the Kent Academic Repository is made available for research purposes. Unless otherwise stated all content is protected by copyright and in the absence of an open licence (eg Creative Commons), permissions for further reuse of content should be sought from the publisher, author or other copyright holder.

#### Versions of research

The version in the Kent Academic Repository may differ from the final published version.

Users are advised to check <http://kar.kent.ac.uk> for the status of the paper. **Users should always cite the published version of record.**

#### Enquiries

For any further enquiries regarding the licence status of this document, please contact:

[researchsupport@kent.ac.uk](mailto:researchsupport@kent.ac.uk)

If you believe this document infringes copyright then please contact the KAR admin team with the take-down information provided at <http://kar.kent.ac.uk/contact.html>

# Delayed, distant skin lesions after transcranial direct current stimulation

**Aaron Kortteenniemi<sup>1</sup>, Soili M. Lehto<sup>1,2,3,4</sup>, Amir-Homayoun Javadi<sup>5,6,7\*</sup>**

<sup>1</sup> Institute of Clinical Medicine/Psychiatry, University of Eastern Finland, Kuopio, Finland

<sup>2</sup> Department of Psychiatry, Kuopio University Hospital, Kuopio, Finland

<sup>3</sup> Department of Psychology, Faculty of Medicine, University of Helsinki, Helsinki, Finland

<sup>4</sup> Department of Psychiatry, Faculty of Medicine, University of Helsinki, Helsinki, Finland

<sup>5</sup> School of Psychology, University of Kent, Canterbury, United Kingdom

<sup>6</sup> Institute of Behavioural Neuroscience, Department of Experimental Psychology, University College London, London, United Kingdom

<sup>7</sup> School of Rehabilitation, Tehran University of Medical Sciences, Tehran, Iran

**\*Corresponding Author:**

Amir-Homayoun Javadi

a.h.javadi@gmail.com

+44 1227 82 7770

Address:

School of Psychology

Keynes College

University of Kent

Canterbury, CT2 7NP

United Kingdom

**Keywords:** transcranial direct current stimulation, adverse effect, safety, skin lesion, irritation

**Running title:** Skin lesions after tDCS

To the editor: Transcranial direct current stimulation (tDCS) has attracted considerable interest in recent years, especially as a potential intervention in stroke rehabilitation and the treatment of depression. Common safety guidelines exist to ensure the safety of the procedure[1]. However, mild adverse effects (AEs) are common and more severe AEs are occasionally encountered. Here, we report two cases of skin lesions following tDCS.

Two females (aged 18 and 19 years) participated in experimental tDCS studies focusing on cognition. A NeuroConn (Ilmenau, Germany) stimulator was used. Stimulation was delivered using carbon-rubber electrodes ( $5 \times 7 \text{ cm}^2$ ) fully enclosed inside conventional reusable saline-soaked sponges. No metal parts were exposed. A 20-ml pod of saline was used for the two electrodes. The electrical current was 1.5 mA for 15 min, with 16 seconds of fade-in and fade-out. The same stimulator was used for all the stimulations, and the output of the stimulator was verified after the stimulations. The subjects rested their hands on a normal wooden office desk. The anode was placed over the left dorsolateral prefrontal cortex (F3 in the 10-20 international EEG electrode placement system) and the cathode on the left wrist. A sports bandage was used to hold the electrodes in place, and impedance at the beginning was  $<10\text{k ohms}$ . The sports bandage was routinely replaced after 5–6 sessions. Neither of the participants reported burning sensations or discomfort during the stimulation. The studies from which these cases were derived were approved by the ethics committee of University College London and the University of Kent. Participants gave written informed consent. The experimenter in all these sessions was the senior investigator, who had ample experience in tDCS.

Participant #1 – Only redness of the skin was observable post-stimulation. After two days, the participant reported an itchy, lumpy lesion (diameter ca. 8mm) on the dorsal side of her wrist, in the electrode placement area. From day 4, the participant used zinc oxide cream to promote healing. See Figures 1a–b for images taken on days 2 and 6. With the participant's permission, she was contacted on day 18 and reported that the lesion was healing well. She was asked to send a photo, but she did not maintain communication after this point.

Participant #2 – Similarly to Participant #1, no signs of irritation were observable following tDCS. After two days, Participant #2 developed a non-itchy, non-lumpy lesion (diameter ca. 6mm). In this case, the lesion was located on the palmar side of the wrist, while the electrode had been placed on the dorsal side. See Figures 1c-d for images taken on days 2 and 22. The participant wished to take part in the second session, and the experimenter met with the participant for evaluation on day 48. In the safety evaluation, the participant still expressed a desire to participate in another session, and as the risk to the participant was estimated as low and no signs of skin irritation were observable, the participant was granted permission for a second session. The same stimulation protocol was applied. The participant was checked for adverse effects on days 50 and 55, i.e., days 2 and 7 following the second session. No skin reactions were observed.

Since 2013, we have used the same stimulation protocol over 400 times, and these two incidents of skin lesions have been the only observed cases. The participants had no history of such skin changes, and we thus considered these lesions to be stimulation induced. Previously, it has been suggested that the conditions of the skin–electrode impedance (effective contact size and impedance) are crucial in the formation of skin lesions[2]. While the safety features of the stimulator prevent the stimulation from continuing if the impedance rises too high, a decreased contact area and/or an insufficiently moistened electrode cannot be ruled out as causes for the first participant's lesions.

However, while the second participant's lesion resembled the other reported tDCS-induced lesions [3,4] in timing and appearance, it did not form under the electrode. Although the lesion location was very unusual, we consider this lesion to have been caused by saline possibly having leaked out of the sponge, forming a conductive path through the bandage to the palmar aspect of the wrist. Another possibility for these lesions is a pre-existing skin defect not apparent on pre-stimulation examination. A small wound would provide a low-resistance path through the skin, which would concentrate the current in small area and could lead to injury[5].

Both delayed [6] and non-recurring [7] skin lesions have been documented in association with tDCS. Issues such as using tap water instead of saline, insufficiently moistened electrodes, electrode shape, non-uniform pressure and individual skin properties have been suggested as potential causes for these lesions, although the causes for delayed reactions remain open. Nevertheless, we are not aware of other reports of lesions on the opposite side of the limb to the electrode location.

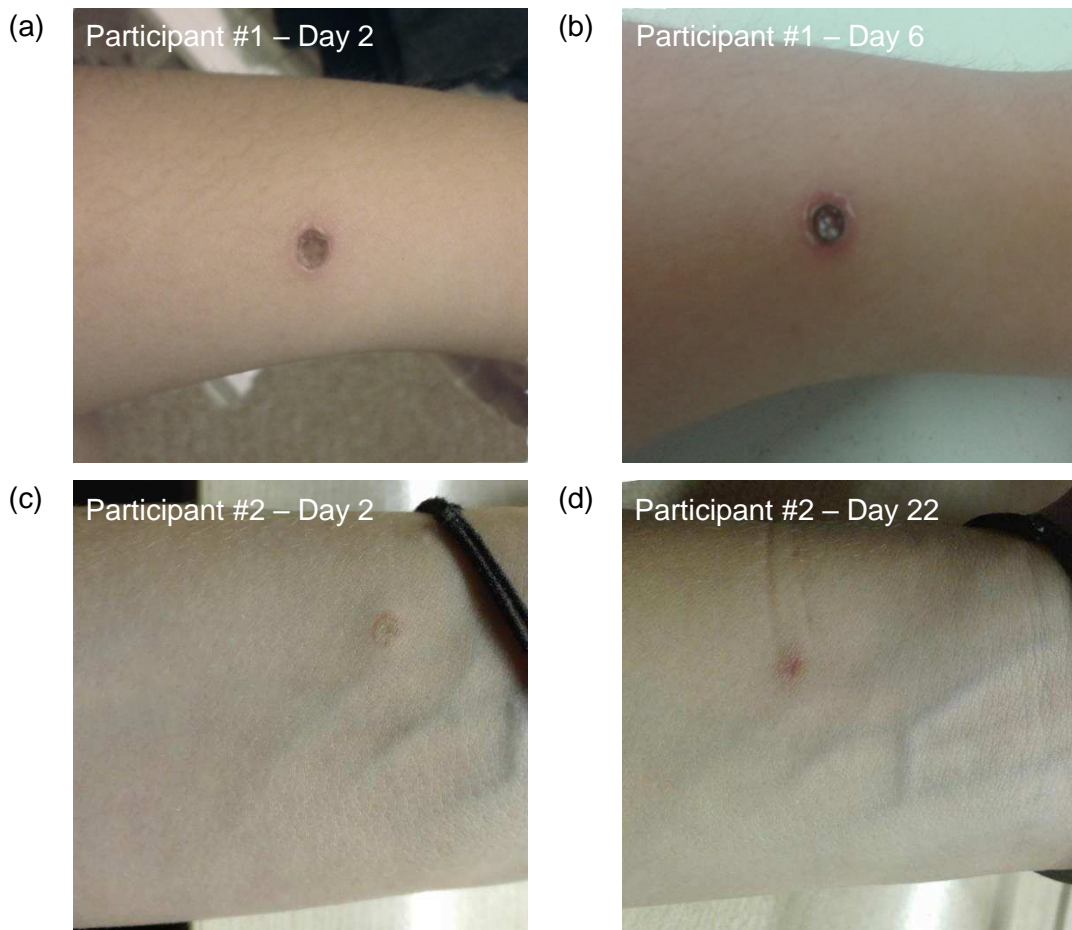
To conclude, these lesions, at least when adhering to safety guidelines, appear rare and manageable. Nonetheless, participants should be informed of the possibility of their occurrence. In addition, care should be taken when administering saline to the sponge electrodes. These two cases are may have followed the use of an improper amount of saline; the first participant may have received an insufficient amount, while the second participant's electrode may have been excessively moistened. Similarly, the condition of the electrodes should be monitored, as in our experience, the absorbance characteristics of the electrodes change with time, and harmful substances may accumulate[6]. To account for the possibility of pre-existing skin defects, the skin should be examined before stimulation using adequate care and lighting.

## **Conflict of Interest**

We wish to confirm that there are no known conflicts of interest associated with this publication and there has been no significant financial support for this work that could have influenced its outcome. We confirm that the manuscript has been read and approved by all named authors and that there are no other persons who satisfied the criteria for authorship but are not listed. We further confirm that the order of authors listed in the manuscript has been approved by all of us.

## References

- [1] Woods AJ, Antal A, Bikson M, Boggio PS, Brunoni AR, Celnik P, et al. A technical guide to tDCS, and related non-invasive brain stimulation tools. *Clin Neurophysiol* 2015;127:1031–48. doi:10.1016/j.clinph.2015.11.012.
- [2] Lagopoulos J, Degabriele R. Feeling the heat: The electrode-skin interface during DCS. *Acta Neuropsychiatr* 2008;20:98–100. doi:10.1111/j.1601-5215.2008.00274.x.
- [3] Riedel P, Kabisch S, Ragert P, Von Kriegstein K. Contact dermatitis after transcranial direct current stimulation. *Brain Stimul* 2012;5:432–4. doi:10.1016/j.brs.2011.09.001.
- [4] Palm U, Keeser D, Schiller C, Fintescu Z, Reisinger E, Padberg F, et al. Skin lesions after treatment with transcranial direct current stimulation (tDCS). *Brain Stimul* 2008;1:386–7. doi:10.1016/j.brs.2008.04.003.
- [5] Aparicio LVM, Guarienti F, Razza LB, Carvalho AF, Fregni F, Brunoni AR. A Systematic Review on the Acceptability and Tolerability of Transcranial Direct Current Stimulation Treatment in Neuropsychiatry Trials. *Brain Stimul* 2016;9:671–81. doi:10.1016/j.brs.2016.05.004.
- [6] Frank E, Wilfurth S, Landgrebe M, Eichhammer P, Hajak G, Langguth B. Anodal skin lesions after treatment with transcranial direct current stimulation. *Brain Stimul* 2010;3:58–9. doi:10.1016/j.brs.2009.04.002.
- [7] Rodríguez N, Opisso E, Pascual-Leone A, Soler MD. Skin Lesions Induced by Transcranial Direct Current Stimulation (tDCS). *Brain Stimul* 2014;7:765–7. doi:10.1016/j.brs.2014.06.005.



**Figure 1.** Skin lesions of the two participants on different days following stimulation.