

# Kent Academic Repository

## Full text document (pdf)

### Citation for published version

Main, Alison and Kelly, Stephen W. and Manley, Graham (1997) The treatment of a severe ataxic dysarthria, using electropalatography. Single case study. In: 2nd European Symposium on ELG and EPG, 1997 June 23-25, Edinburgh.

### DOI

### Link to record in KAR

<https://kar.kent.ac.uk/47793/>

### Document Version

UNSPECIFIED

#### Copyright & reuse

Content in the Kent Academic Repository is made available for research purposes. Unless otherwise stated all content is protected by copyright and in the absence of an open licence (eg Creative Commons), permissions for further reuse of content should be sought from the publisher, author or other copyright holder.

#### Versions of research

The version in the Kent Academic Repository may differ from the final published version.

Users are advised to check <http://kar.kent.ac.uk> for the status of the paper. **Users should always cite the published version of record.**

#### Enquiries

For any further enquiries regarding the licence status of this document, please contact:

[researchsupport@kent.ac.uk](mailto:researchsupport@kent.ac.uk)

If you believe this document infringes copyright then please contact the KAR admin team with the take-down information provided at <http://kar.kent.ac.uk/contact.html>

# **THE TREATMENT OF A SEVERE ATAXIC DYSARTHRIA, USING ELECTROPALATOGRAPHY.**

## **Single case study**

**Alison Main, Steve Kelly and Graham Manley**

Electropalatography has been used successfully with several client groups (Hardcastle et al 1991). Intelligibility has been improved in children with articulation difficulties as a result of cleft palate, or with dyspraxia, or long standing phonological difficulties. There has been less work with adults and a very limited amount with acquired dysarthrics (Gibbon 1997). In the majority of cases reported, there has been a degree of improvement in intelligibility (eg Goldstein et al 1994). This is not a miraculous return to “normal speech”, but an improvement, often where conventional speech therapy has failed.

The Canterbury and Thanet Speech and Language Therapy Department, together with the local Community Dental Department and the University of Kent Medical Electronics Research Team, have undertaken a clinical trial. The intention was to have a subject group of at least 24 adult, acquired dysarthrics, and to compare the effects of electropalatography with conventional speech and language therapy in each case. Dr Rosemarie MorganBarry acted as a Speech and Language Therapy adviser and the research was funded by SE Thames Regional Health Authority. The results of this clinical trial will be fully reported in a separate paper. This paper reports on a single case history from within the trial.

## **LINGUAGRAPH**

The electropalatography system used was the Kent Linguagraph (Kelly & Main 1997). This system has been devised by the above team specifically for clinical use. It works with a PC fitted with a standard interface card. Features include: a large, bright display (which can be single, two channel or full screen), and the facility to record and replay data. The system is easy to use for both therapy and assessment.

## **CASE HISTORY**

CB was referred to the trial by his Speech and Language Therapist in October 1995, approximately 6 months post onset. He was a 48 year old male, living at home with his wife and two teenage children. He had taken early retirement, due to mobility problems caused by ankylosing spondylitis. In February 1995, he had large, bilateral cerebellar infarcts, and infarcts in the posterior fossa, as a result of vasculitis. As well as compounding mobility difficulties, this affected swallowing and speech. CB was dysphagic: his swallow was poorly coordinated, and following videofluoroscopy, a PEG was inserted, in May 1995. This provided the bulk of his nutrition, and only very small amounts of purees and thickened fluids were taken for pleasure.

Additionally, CB was left with a severe ataxic dysarthria. Speech was “rarely intelligible”, and he was provided with a Lightwriter SL 35, to aid communication. CB was reluctant to use this, and very keen to work on his speech.

## **THE TRIAL**

All potential subjects for this trial were screened. This assessment specifically checked tongue movement and sensitivity, visual acuity and perception, the ability to follow instructions, and to interpret what can be seen on the computer screen. In CB’s case, tongue mobility and sensitivity were greatly reduced. He was easily able to interpret the data on a small computer screen, and to follow instructions. He was keen to take part, and was considered suitable, but CB was very anxious about the palate. He did not feel he would be able to open his mouth sufficiently for an impression to be made and, due to his dysphagia, was concerned that he might inhale some of the impression material.

CB was given lots of reassurance and the impression was successfully carried out at home, using an elastomer material, which is less likely to fragment. An additional practise palate was provided, to allow him to become accustomed to the presence and feel of an electropalatography palate.

Each subject was allocated to a group, which determined which type of therapy they started with: conventional or electropalatography. They each received 6 weeks of each type of therapy, twice weekly, on a domiciliary basis. CB was placed in the group which received conventional speech and language therapy first.

Before therapy began, each subject was assessed by a “blind assessor”. They were assessed again at the change over of therapies and again when therapy was complete. Assessment consisted of the Frenchay Dysarthria Assessment (Enderby 1983), the reading of a phonetically balanced text, which was then transcribed, and the completion of an “attitudes to communication” questionnaire, which was devised by the team. Additionally, a reading of a wordlist, which contained all lingual consonants in all word positions, was recorded into the computer, giving us a record of tongue contact patterns (Hardcastle et al 1985). By comparing data from before therapy commenced, after the first block of therapy and after the second block, we were able to assess any changes in intelligibility, and the reasons for those changes.

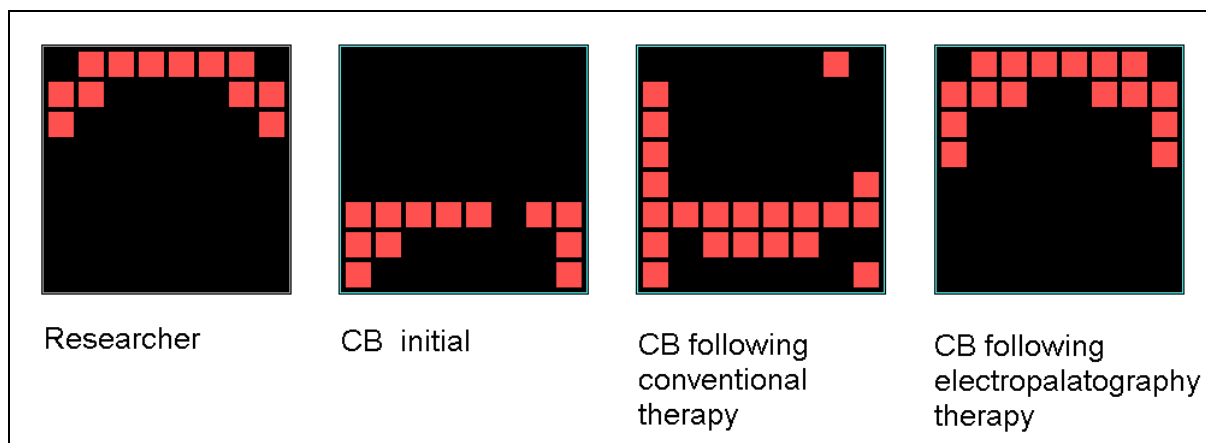
## **THERAPY REGIME**

The intelligibility section of the initial Frenchay rated CB as unintelligible at single word, sentence and conversation level. Phonetic transcription indicated errors in place, manner and voicing of many phonemes, in all word positions. Electropalatography tongue contact patterns showed that virtually all lingual consonants were made at the rear of the oral cavity.

CB started with conventional therapy. The co-ordination of breathing, phonation and articulation was difficult for him, and his insight into his unintelligibility was limited. Therapy attempted to address all these areas. It also focused on contrasting bilabial sounds. CB was using the correct place of articulation for these, but there were frequent errors in voicing and in manner. Following this period of therapy, assessments showed little change.

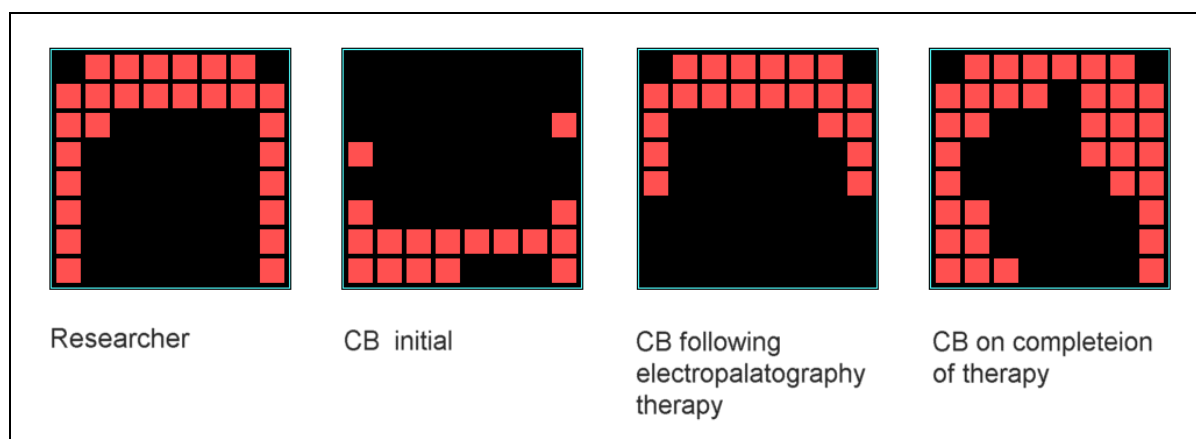
After electropalatography therapy, however, he made considerable improvement at a conversational level. Therapy had focused on bringing his tongue forward for a specific sound, /l/, and contrasting it with /k/. We also worked on the timing of the contact pattern with voicing. Electropalatography enabled CB to visualise tongue position. Due to reduced sensation, he had previously had limited awareness of the whereabouts of his tongue, and the effect incorrect placement had on his speech. By using Linguagraph as a biofeedback tool, and also providing a visual target, CB was able to see how far he was from that target initially, and what changes were required. CB was encouraged to focus on the limited sensation he had, and the sound made, and as he became more practised in achieving correct tongue placement, and sound, the visual image was gradually withdrawn. The improvement in contact patterns for /l/ is dramatic (see Figure 1).

**Fig 1. Tongue positions for /l/**



CB was felt to have done so well that a further 8 sessions of electropalatography and 8 sessions of conventional therapy were offered. Electropalatography therapy then focused on /n/. This was often stopped, sounding like a /g/, or affricated, sounding like a /kx/. Therapy did help to bring the tongue position forward for this sound (see Figure 2), though it continued to be difficult for CB to coordinate the place and manner of articulation, and to contrast this sound with an /l, t, and d/. The Frenchay following this showed limited improvement.

**Fig 2. Tongue positions for /n/**



However, while CB remained severely dysarthric, the SLT assessor was able to hold a conversation with him, whereas previously she had found him unintelligible.

The final eight sessions were of conventional therapy, and were used to consolidate all that we had worked on. We used all the sounds that had been focused on in therapy: /p b m, k g, l, t d and n/ and worked on maintaining, improving and contrasting these. Much work on minimal pairs, and on self-monitoring, was done.

## OUTCOME

The final Frenchay showed no improvement at a single word or sentence level, but a dramatic improvement in conversation. Electropalatography indicated that tongue position was more consistently forward for alveolar sounds. This is shown by the centre of gravity score, where a score of 1 represents contact centred on the front row of electrodes, (ie alveolar), and a score of 8 represents contact centred on the most posterior row of electrodes, (ie velar). (See Table 1 for a summary of results).

CB reported that he surprised his consultant at his last appointment, by speaking for himself rather than relying on his wife to answer questions. The consultant's report stated that "speech and

swallowing are certainly improved". His confidence appeared to improve a little on paper, but the effect this had was to make CB more outgoing, and to give him back his wicked sense of humour.

**Table 1. Summary of progression of assessment results**

Assessment	Baseline	Post Conventional Therapy	Post Block 1 Electro-palatography	Post Block 2 Electro-palatography	Final outcome
<b>Frenchay:</b> Conversational Intelligibility (0= unintelligible, 8= normal)	0	0	2	2.5	5
<b>Electropalatography:</b> "Centre of gravity" for /n/ (Researcher = 3.2)	5.0	4.9	1.2	2.2	3.8
<b>Questionnaire:</b> "how do you feel about talking to new people?"	"avoid doing it"	"avoid doing it"	"nervous"	"nervous"	"slightly nervous"

While no specific dysphagia rehabilitation therapy was given, swallowing also improved. This is probably due to improved strength and coordination of tongue movement. CB is now taking free fluids and soft diet, and has managed without his PEG since Christmas 1996.

## CONCLUSIONS

CB responded extremely well to therapy. Improvement only began during the first block of electropalatography. Not only did this help to improve the accuracy of tongue/palate contact, but it also helped increase CB's insight into his lack of intelligibility. The greatest improvement followed the final period of conventional therapy, which was used as a period of consolidation. In the nine months since his therapy programme finished, although CB has had setbacks, he has maintained his final level of intelligibility.

This data suggests that electropalatography is an extremely useful additional tool, when used in conjunction with conventional therapy techniques. Electropalatography allows objective assessment, enabling appropriate targeting of therapy. It provides visual feedback, which assists in therapy and can be extremely motivating for therapist and client. And it gives an objective measurement of outcome, which is an increasingly important consideration for the therapist.

## References

- Enderby, P. (1983). Frenchay Dysarthria Assessment, College Hill Press.
- Gibbon, F. (1997). Bibliography of electropalatographic studies in English (1957-1997), Department of Speech & Language Sciences, Queen Margaret College, Edinburgh.
- Goldstein, P., Ziegler, W., Vogel, M. and Hoole, P. (1994). Combined palatal lift and EPG feedback therapy in dysarthria: A case study, *Clinical Linguistics & Phonetics*, **8**, 201-218.
- Hardcastle, W. J., Gibbon, F. E. and Jones, W. (1991). Visual display of tongue-palate contact: Electropalatography in the assessment and remediation of speech disorders, *British Journal of Disorders of Communication*, **26**, 41-74.
- Hardcastle, W. J., Morgan-Barry, R. A. and Clark, C. J. (1985). Articulatory and voicing characteristics of adult dysarthric and verbal dyspraxic speakers: an instrumental study, *British Journal of Disorders of Communication*, **20**, 249-270.
- Kelly, S. W. and Main, A. (1997). SNORS and Linguagraph, *RCSLT Bulletin*, May 1997.

Alison Main  
Speech & Language Therapist  
Kent & Canterbury Hospital and University of Kent at Canterbury  
Ethelbert Road  
Canterbury, Kent  
CT1 3NG  
01227 766877 Extn 4762  
Canterbury & Thanet Community Healthcare Trust

Steve Kelly  
Senior Lecturer in Medical Electronics  
University of Kent at Canterbury  
Canterbury, Kent  
CT2 7NT  
01227 764000 Extn 3709 or 01227 823709 (direct)

Graham Manley  
Senior Dental Officer  
Canterbury Health Centre  
26 Old Dover Road  
Canterbury, Kent  
CT1 3JH  
01227 454435